



PEARL

An unusual case of chronic suppurative osteomyelitis of the mandible

Ali, K; Akram, A; Akhtar, MU

Published in:

Archives of Orofacial Sciences

Publication date:

2012

Link:

[Link to publication in PEARL](#)

Citation for published version (APA):

Ali, K., Akram, A., & Akhtar, MU. (2012). An unusual case of chronic suppurative osteomyelitis of the mandible. *Archives of Orofacial Sciences*, 0(0).

All content in PEARL is protected by copyright law. Author manuscripts are made available in accordance with publisher policies. Wherever possible please cite the published version using the details provided on the item record or document. In the absence of an open licence (e.g. Creative Commons), permissions for further reuse of content should be sought from the publisher or author.

Case Report

An unusual case of chronic suppurative osteomyelitis of the mandible

Kamran Ali ^{a*}, Ashfaq Akram ^b, Muhammad Usman Akhtar ^c

^a Peninsula Dental School, Room C402 Portland Square, Drake Circus, University of Plymouth, Plymouth, Devon PL4 8AA, United Kingdom. ^b Allianza University College of Medical Sciences, Waziria Medical Square, Jalan Bertam 2, Mukim 6, 13200 Kepala Batas, Pulau Pinang, Malaysia. ^c Department of Oral and Maxillofacial Surgery, de' Montmorency College of Dentistry, Fort Road, Lahore, 54000 Pakistan.

* Corresponding author: kamran.ali@pds.ac.uk

Received: 20/09/2011. Accepted: 28/01/2012. Published online: 28/01/2012.

Abstract Osteomyelitis of the mandible, a serious complication of untreated odontogenic infection has been reported. This case report describes an interesting presentation of chronic suppurative osteomyelitis (CSO) of the mandible in a 13 years old anaemic male patient. Investigations revealed inversion of his permanent teeth leading to trans-cutaneous extra-oral eruption along with marked destruction of mandible on the affected side. The treatment included a pre surgical course of antibiotics followed by the removal of the retained second premolar tooth, surgical debridement of the affected bone, and resection of the cutaneous sinus tract. The post-operative healing was uneventful. A combination of antibiotic therapy and surgical debridement were effective in the treatment of chronic suppurative osteomyelitis.

Keywords: Infection; mandible; osteomyelitis.

Introduction

Osteomyelitis is an acute or chronic inflammatory process that can involve cortical and trabecular aspects of bone or bone marrow (Arunkumar *et al.*, 2011). Osteomyelitis is an uncommon but recognized complication of untreated odontogenic infection. Osteomyelitis of the jaws can present in acute, subacute or chronic forms and is mainly caused by odontogenic infections (Bernier *et al.*, 1995; Hudson, 1993; Aitasalo *et al.*, 1998). Classically, patient with osteomyelitis of the mandible would experience pain and swelling over the affected side of the face (Mohammed-Ali *et al.*, 2010). Other features may include discharge / drainage, trismus and paraesthesia in the distribution of the inferior alveolar nerve (Uche *et al.*, 2009). The clinical presentation and response to treatment depends on the

virulence of the infecting agent and immune status of the patient. Osteomyelitis lasting for over weeks after the onset of symptoms is generally classified as 'chronic' (Marx *et al.*, 1994).

Chronic suppurative osteomyelitis (CSO), like most other forms of jaw osteomyelitis, is more commonly seen in the mandible and is associated with recurrent discharge of pus. CSO in paediatric subjects is a rare but recognized complication of long-standing odontogenic infection (Mallikarjun *et al.*, 2011). Chronic osteomyelitis in children and adolescents must be diagnosed at an early stage to avoid serious and long-term complications (Saarinen *et al.*, 2011). Management strategies are centralized on timely and thorough surgical debridement and culture-directed antibiotics (Coviello and Stevens, 2007; Kim and Jang, 2001; van Merkesteyn *et al.*, 1997).

Case report

A 13-year-old male was presented with complaints of recurrent pain and swelling in his right lower jaw. There was a history of recurrent toothache in his right lower jaw with frequent discharge of pus for the last two years. There was no history of trauma or any surgical intervention to his lower jaw. His medical history was remarkable with no systemic disease or known allergy.

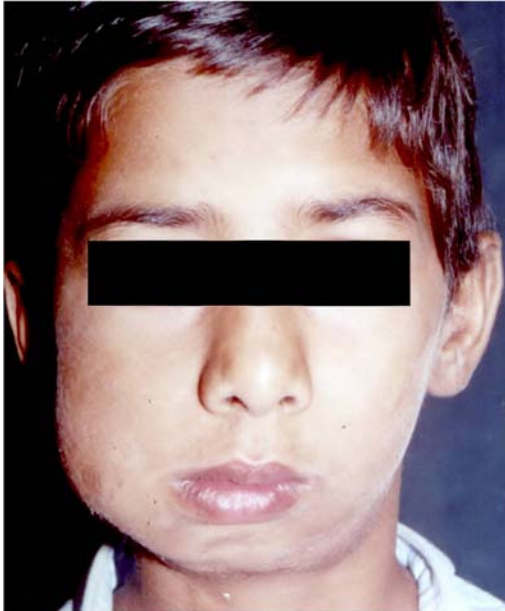

Fig. 1 Preoperative frontal view showing a swelling on the right mandible.

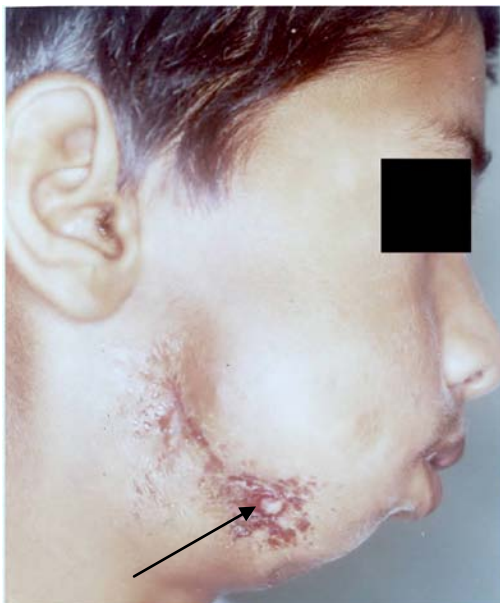

Fig. 2 Preoperative lateral view showing a cutaneous sinus with exposure of the lower right second premolar.

On extra-oral examination, a marked swelling was noted involving the right side of the mandible and there was evidence of cutaneous scarring due to recurrent discharge of pus (Fig.1 and Fig.2). There was cutaneous exposure of a bony hard tooth-like mass in the right mandibular body area. There was no regional lymphadenopathy and mouth opening was adequate. Intra-oral examination showed a retained, carious right second primary molar while the second premolar and second permanent molar were not visible on the right side. The left lower premolars, first and second permanent molars were erupted.

An orthopantomogram (OPG) revealed a remarkable destruction of the right mandible involving the body, angle and ramus regions (Fig.3). The right coronoid process was not discernable on the radiograph. There was evidence of patchy irregular radiolucencies in the mandibular body along with cortical hyperplasia involving the inferior mandibular border adjacent to the lower premolar region. Moreover, the second premolar and second permanent molar were inverted with their occlusal surfaces extending well beyond the inferior border of the mandibular body. It was then realized that the tooth-like hard mass visible extra-orally was actually the right lower second premolar.

Haematological investigations showed that the patient was anaemic with a haemoglobin level of 8.6g/dl and low serum ferritin levels. Peripheral blood picture confirmed a hypochromic, microcytic anemia due to iron deficiency. His erythrocyte sedimentation rate (ESR) was 27mm/hour. Other blood values of the patient including blood glucose levels were within the normal range. Based on the history, clinical examination and investigations, a diagnosis of chronic suppurative osteomyelitis of the mandible with recurrent acute exacerbations was made.

Patient was admitted and pre-operative preparation was made.

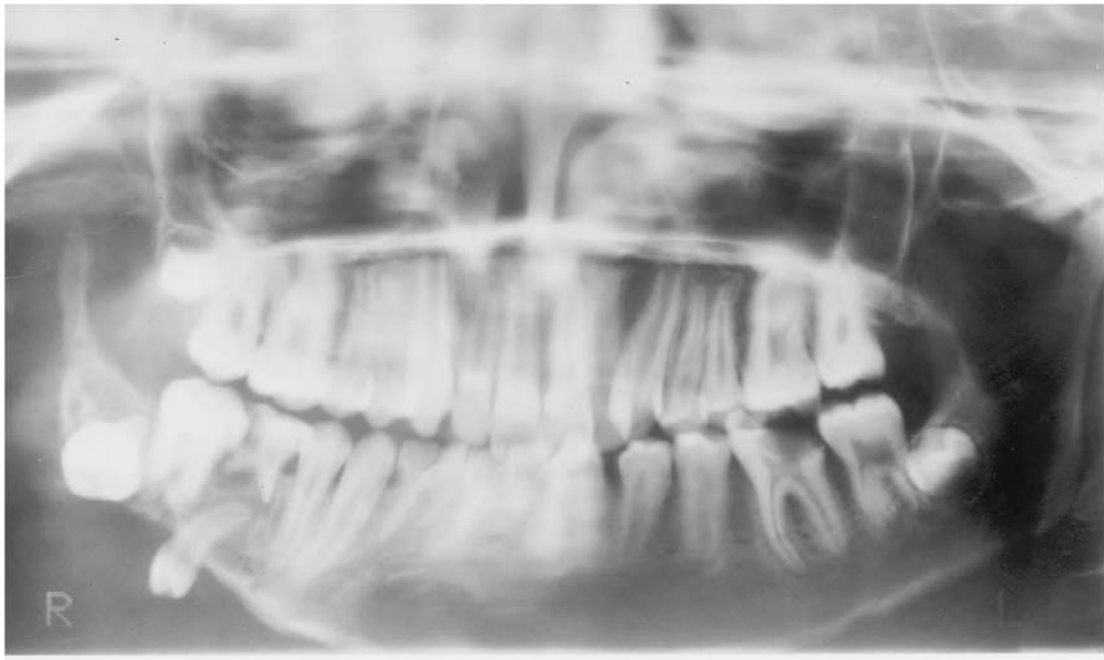


Fig. 3 Orthopantomogram showing inversion of lower right second premolar, second molar and destruction of right mandible.

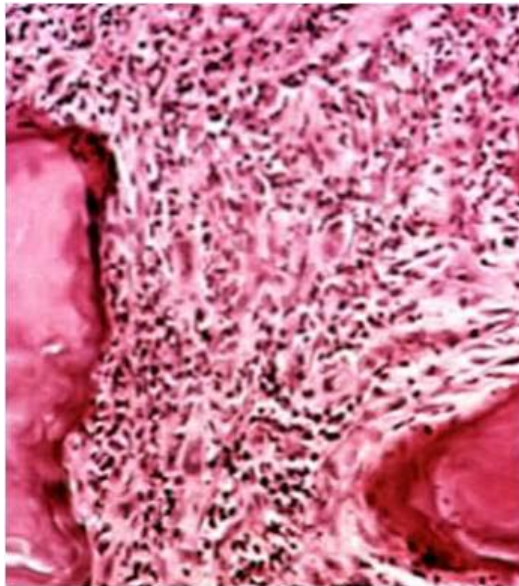


Fig. 4 Photomicrograph showing chronically inflamed fibrous connective tissue filling the inter trabecular spaces of bone. (hematoxylin – eosin stain; original magnification x 100)

Anaemia was corrected pre-operatively by infusion of two units of packed red blood cells. Empirical antibiotic therapy was initiated preoperatively with co-amoxiclav 600mg and metronidazole 250mg administered intravenously in every 12 hours. The involved region of the mandible was exposed trans-orally

under general anaesthesia and the surgical debridement and curettage were carried out. The right lower second primary molar and second premolar, were extracted since these teeth did not seem to be amenable to any treatment. Due to marked inversion and trans-cutaneous exposure, the lower right second premolar was removed extra-orally. The lower second molar was however, left *in situ* due to possible risk of mandibular fracture and inferior dental nerve damage. The cutaneous sinus tract was tracked intra-orally and excised completely.

Pathological specimen obtained during surgical curettage of mandible was submitted for microbiological and histopathological analysis. Microbiological results confirmed a mixed infection with a predominance of Streptococci (*S. oralis*, *S. salivarius*, *S. sanguinis*, and *S. sobrinus*), Staphylococci (*S. aureus*, *S. epidermidis*), *Eikenella corrodens*, Enterococci (*E. faecalis*, *E. faecium*). Also identified were strict anaerobes of the genera *Fusobacterium nucleatum*, *Porphyromonas gingivalis*, and *Prevotella intermedia*.

The biopsy report confirmed the diagnosis of chronic osteomyelitis with evidence of chronically inflamed fibrous connective tissue filling the inter trabecular spaces of bone (Fig. 4). Isolated pockets of suppuration were also identified.

Administration of co-amoxiclav 600mg and metronidazole 250mg intravenously in every 12 hours were continued for one week postoperatively prior to the patient being discharged from the ward. The patient was reviewed regularly during periodic follow-up visits in the outpatient department. Oral antibiotics including co-amoxiclav 375mg and metronidazole 200mg 8 hourly were continued for another four weeks. At this stage, satisfactory healing was observed and there were no clinical signs or symptoms to indicate persistent infection. Long-term replacement therapy with oral ferrous sulphate was prescribed under care of a general physician. Dietary consultation was also provided to the child and parents by an experienced nutritionist. The patient was kept under long-term follow-up for over 11 months and remained symptom-free. He did not show any signs of infections at periodic clinical examinations.

Discussion

Mandibular osteomyelitis may result in a variety of complications including local bone destruction, paraesthesia of mental or inferior dental nerves and cutaneous sinuses or fistulae. This case report highlights some uncommon complications of osteomyelitis as a sequel to untreated carious teeth. Although displacement of permanent tooth germs is recognized following osteomyelitis, this case does show unusual inversion of teeth with trans-cutaneous exposure. A unique aspect of this case report is that the extraction of the lower right second premolar was carried out extra-orally. The normal position of the lower first molar may be explained on the

basis of its early eruption time. It has been reported that involvement of a single feeder vessel may lead to necrosis of a large portion of bone and sequestration of an entire jaw quadrant is recognized (Thoma, 1963). The exact pathogenesis of the marked resorption of the right mandible is unclear. It may represent bone destruction secondary to the local inflammatory process. However, a previously unrecognized developmental anomaly cannot be ruled out. Perhaps extensive local destruction of the mandible could have been minimized with an earlier diagnosis and prompt management.

Anaemia, diabetes, tuberculosis, malignancy and a variety of systemic diseases may complicate osteomyelitis leading to a more protracted course (Baltensperger and Eyrich, 2008). In the present case, anemia was corrected successfully without any adverse long-term consequences after treatment. A variety of antibiotic regimens are recommended for chronic jaw osteomyelitis, including amoxicillin, co-amoxiclav, cephalexin, and metronidazole (Mandracchia *et al.*, 2004; Gutierrez, 2005). Other options include Clindamycin due to its excellent absorption and bioavailability in bone infections (Scolozzi *et al.*, 2005). We used empirical antibiotic therapy based on co-amoxiclav and metronidazole continuously throughout the treatment. This is because the micro-organisms identified from the culture and sensitivity report were a mixed population of aerobes and anaerobes that were highly sensitive to these antibiotics. Although we managed to treat this case successfully, one limitation of this case report is that bone healing was not monitored using modern imaging techniques like bone scintigraphy and it is realized that such monitoring would have provided a more objective scrutiny of bone healing. Nevertheless, there was adequate clinical follow-up to ensure there was no recurrence of infection.

References

- Aitasalo K, Niinikoski J, Grénman R, Virolainen E (1998). A modified protocol for early treatment of osteomyelitis and osteoradionecrosis of the mandible. *Head Neck*, **20**(5): 411-417.
- Arunkumar JS, Naik AS, Prasad KC, Santhosh SG (2011). Role of nasal endoscopy in chronic osteomyelitis of maxilla and zygoma: a case report. *Case Report Med*, **2011**: 802964.
- Baltensperger M, Eyrich G (2008). *Osteomyelitis of the Jaws*. Berlin: Springer-Verlag.
- Bernier S, Clermont S, Maranda G, Turcotte JY (1995). Osteomyelitis of the jaws. *J Can Dent Assoc*, **61**(5): 441-442, 445-448.
- Coviello V, Stevens MR (2007). Contemporary concepts in the treatment of chronic osteomyelitis. *Oral Maxillofac Surg Clin North Am*, **19**(4): 523-534.
- Gutierrez K (2005). Bone and joint infections in children. *Pediatr Clin North Am*, **52**(3): 779-794.
- Hudson JW (1993). Osteomyelitis of the jaws: a 50-year perspective. *J Oral Maxillofac Surg*, **51**(12): 1294-1230.
- Kim SG, Jang HS (2001). Treatment of chronic osteomyelitis in Korea. *Oral Surg Oral Med Oral Pathol Oral Radiol Endod*, **92**(4): 394-398.
- Mallikarjun K, Kohli A, Kumar A, Tanwar A (2011). Chronic suppurative osteomyelitis of the mandible. *J Indian Soc Pedod Prev Dent*, **29**(2): 176-179.
- Mandracchia VJ, Sandres SM, Jaeger AJ, Nickles WA (2004). Management of osteomyelitis. *Clin Pediatr Med Surg*, **21**: 335-351.
- Marx RE, Carlson ER, Smith BR, Toraya N (1994). Isolation of *Actinomyces* species and *Eikenella corrodens* from patients with chronic diffuse sclerosing osteomyelitis. *J Oral Maxillofac Surg*, **52**(1): 26-33.
- Mohammed-Ali RI, Collyer J, Garg M (2010). Osteomyelitis of the mandible secondary to pericoronitis of an impacted third molar. *Dent Update*, **37**(2): 106-108.
- Saarinen RT, Kolho KL, Kontio R, Saat R, Salo E, Pitkäranta A (2011). Mandibular osteomyelitis in children mimicking juvenile recurrent parotitis. *Int J Pediatr Otorhinolaryngol*, **75**(6): 811-814.
- Scolozzi P, Lombardi T, Edney T, Jaques B (2005). Enteric bacteria in mandibular osteomyelitis. *Oral Surg. Oral Med. Oral Pathol Oral Radiol Endod*, **99**(6): 42-46.
- Thoma KH (1963). *Oral Surgery*, 4th edn. St. Louis: Mosby, pp. 603, 671.
- Uche C, Mogyoros R, Chang A, Taub D, DeSimone J (2009). Osteomyelitis of the jaw: a retrospective analysis. *Internet J Infect Dis*, **7**(2).
- van Merkesteyn JP, Groot RH, van den Akker HP, Bakker DJ, Borgmeijer-Hoelen AM (1997). Treatment of chronic suppurative osteomyelitis of the mandible. *Int J Oral Maxillofac Surg*, **26**(6): 450-454.