



PEARL

Fully guided placement of orthodontic miniscrews-a technical report

Kirnbauer, B; Rugani, P; Santigli, E; Tepesch, P; Ali, K; Jakse, N

Published in:

Australasian Orthodontic Journal

Publication date:

2019

Link:

[Link to publication in PEARL](#)

Citation for published version (APA):

Kirnbauer, B., Rugani, P., Santigli, E., Tepesch, P., Ali, K., & Jakse, N. (2019). Fully guided placement of orthodontic miniscrews-a technical report. *Australasian Orthodontic Journal*, 35(1), 71-74.

All content in PEARL is protected by copyright law. Author manuscripts are made available in accordance with publisher policies. Wherever possible please cite the published version using the details provided on the item record or document. In the absence of an open licence (e.g. Creative Commons), permissions for further reuse of content should be sought from the publisher or author.

Title: **Fully Guided Placement of Orthodontic Miniscrews**

Kirnbauer B¹, Rugani P², Santigli E³, Tepes P⁴, Ali K⁵, Jakse N⁶

Kirnbauer B, DMD, Department of Dental medicine and Oral health, Division of Oral Surgery and Orthodontics, Medical University of Graz Austria

Rugani P, DMD, Department of Dental medicine and Oral health, Division of Oral Surgery and Orthodontics Medical University of Graz Austria

Santigli E, MD, DMD, Department of Dental medicine and Oral health, Division of Oral Surgery and Orthodontics Medical University of Graz Austria

Tepes P, Dental technician, Department of Dental medicine and Oral health, Medical University of Graz Austria

Ali K, PhD Associate Professor / Consultant in Oral Surgery, Peninsula Dental School University of Plymouth UK

Jakse N, MD, DMD, Professor/ Head of the Division of Oral Surgery and Orthodontics of the Department of Dental medicine and Oral health, Medical University of Graz Austria

Corresponding Author

Dr. Barbara Kirnbauer, DMD

Department of Dental Medicine and Oral Health
Medical University of Graz
Graz
Billrothgasse 4
8010 Graz Austria
Tel.: 0316 385 30674
Fax: Fax: +43/316/385-595-30633 (Secretariat)
E-mail: Barbara.kirnbauer@medunigraz.at

Abstract

Orthodontic miniscrews (OMS) are used routinely to obtain skeletal anchorage during orthodontic treatment and their popularity is growing due to simple technique of placement and removal; improved patient compliance and minimal impact on function and aesthetics. However, several complications and risks are reported with orthodontic miniscrews underscoring the need for a thorough pre-operative assessment for accurate placement. We present a novel approach which employs a custom-designed 3D-printed splint facilitating a fully guided OMS placement. We believe this approach can provide more predictable results for accurate placement of orthodontic screws and avoiding associated risks and complications.

Introduction

Miniscrews are widely used to provide anchorage during orthodontic treatment.^{1,2} They provide skeletal anchorage and reduce reliance on conventional means of anchorage such as teeth or extra-oral devices.³ Placement and removal of orthodontic miniscrews (OMS) is usually straightforward and improve patient compliance without compromising the aesthetics.^{2,4,5} Given that OMS are fixed in the cortical bone and remain for a predefined time period, good preoperative assessment is crucial to evaluate the quality and quantity of bone and to avoid damage to adjacent anatomical structures including teeth.⁵ Preoperative planning helps to ensure accurate placement of OMS to facilitate successful osteointegration and reduce associated risks.^{3,6}

OMS are available in a wide range of diameter and length and can be placed in a variety of locations in the upper and lower jaw. Placement of OMS is usually carried out flapless under local anaesthesia and is accomplished in most cases without predrilling.^{7,8} Therefore, there is a risk of damage to adjacent dental roots and local neurovascular structures such as palatine vessels.⁵ Furthermore, perforation of the floor of the nasal cavity or maxillary antrum is also possible.⁹ Damage to dental roots is usually self-limiting and healing may occur within a few weeks.^{7,10} However, trauma to blood vessel can cause bleeding, which can be difficult to handle especially if it involves the palatine vessels.¹¹ In addition, premature loosening and loss of screws due to inadequate stability may warrant interruption of orthodontic treatment with financial implications.^{7,9}

Accurate placement of OMS is required for optimal retention, avoid complications and improve long-term treatment outcomes and enhance patient acceptance.^{1,12,13} We present a novel custom-designed 3D-printed splint that allows fully guided OMS placement.

Case Report

Preoperative Planning

Preoperative CBCT scans of the upper jaw (Planmeca Promax 3D Max, Finland) with the dimensions of 10cm x 5,5cm (diameter x height) and a voxel size of 200 μ m (mA, kV, sec) were obtained. Digital Imaging and Communications in Medicine (DICOM) data were uploaded in the coDiagnostiX[®] implant planning software (Dentalwings GmbH, Germany). Matching with the STL file (standard triangulation language) of the corresponding upper jaw model, produced from an alginate impression covering teeth, alveolar crest and palatal tissue, was performed semi-automatically with final manual fine-tuning in reference to teeth and adjacent gum. The super hard plaster model had been scanned with a fully automated optical structured-light scanner (S600 Arti Scanner, Zirkonzahn, Italy) and digitally saved in STL format.

Screw positions were planned virtually in the coDiagnostiX[®] software with a focus on the correct mesial-distal as well as vertical position; angulation; and insertion depth. In addition, the position of the adjacent dental roots and the maxillary were accounted for.

Two 14mm screws (Sterile Dual-Top Anchor System[®], Jeil Medical Corporation, Germany) were selected to be inserted in the region half way from the mid- palatal suture to the corresponding first premolar, along the transverse line through the palatal cusp of that first premolar (M4 site).¹⁴ Both screws were virtually positioned as parallel as possible to facilitate the later application of the planned orthodontic device. Next, a tooth-supported splint was designed for fully-guided screw insertion (Figure 1). An inner sleeve diameter of 4.6mm of the template was adjusted to the predetermined outer diameter of insertion instrument. The insertion depth was defined by the sleeve tube height that presented the depth stop when reaching contact to the head of the hand piece. It was designed considering screw length and length of insertion instrument as demonstrated in figure 1. A custom metallic sleeve was designed and 3D-printed with a metallic printer. This served to provide guidance during placement of the full screw length and helped avoid tilting of the insertion instrument. It was ensured that the outer diameter of the guide's sleeve tube and the inner diameter conformed to the shaft of the insertion instrument. After polishing and sterilization, the

sleeve was positioned at the insertion instrument and secured via fixation of the instrument in the hand piece. (Figure 2)

The virtually designed surgical splint was saved as STL file and stereolithographic printed (AsigaPro2®, Dentona, Germany; Kunststoff). Finally, the 3D-printed guide was cleaned, light hardened (Otoflash G171®, Dentona, Germany) under the use of N₂O and prepared for the intraoperative use.

Surgical Placement

Local anaesthesia was obtained with palatal infiltration (Ultracain Dental forte, 1:100 000, Sanofi, Austria) and the insertion guide was positioned on the teeth. Two 14 mm mini-screws were inserted with a prosthetic torque-controlled hand piece at 20 rpm in the planned position. Depth control was given with the stop of hand piece at the insertion guide. (Figure 3,). Accurate placement was achieved and no complications were experienced during placement of the screws (Figure 4).

Discussion

We have presented a custom-designed surgical splint and custom-fit insertion sleeve allows full-guided palatal insertion of orthodontic mini-screws according to pre-operative three-dimensional planning.

Insertion of OMS as temporary anchorage device is routinely performed flapless often relying on several studies on average vertical bone height and defined “safe zones”.¹⁴ Nevertheless, blind screw positioning may compromise the amount of bony support for anchorage and lead to perforation of the sinus or the nasal cavity.^{7,9} DICOM data allow individualised planning for optimal screw position¹, and if matched with STL data from an intraoral or plaster model, scan-guided insertion via surgical splints is possible. It is recognised that the use of a positioning aid for OMS has already been reported in literature as well as three-dimensional planning and guided insertion.^{1,12,13} However, the novel approach presented in this paper permits fully-guided application of OMS adapted to the individual anatomy and the planned orthodontic device.

To this end, a custom--made 3D-printed sleeve has been designed according to the properties of the used anchorage system that ensures guidance from the very beginning, i.e., when the screw tip touches the surface of the gum, until the final depth and position of the screw is achieved. Corresponding to implant surgery guides, the length of the polymer guide sleeve is predefined by the end position of the planned screw. However, in contrast to implant surgery sleeves, there is no need of a guide covering inner sleeve.¹⁵ This is because first only the application instrument and not the screw is touching the guide and second, the insertion is done with low rotations per minute (20 rpm). However, only in combination with the use of the described custom-fit shaft sleeve that avoids tilting, the path of the inserted screw is predefined accurately. We decided on a metallic printed shaft sleeve to allow re-sterilisation. However, a polymer-printed sleeve designed for single use might work equally well.

Use of a well-established implant planning software offers the advantage of great flexibility regarding the individual guide design and preferences of the treating clinician.¹⁶

The approach described here relies on the availability of advanced equipment. Artefact-poor DICOM data with an ordinary mode and accurate voxel size (200 μm in this case), covering all essential anatomical structures are mandatory. Highly accurate devices for 3D printing or milling are required as are staff skilled to perform accurate matching, planning and fabrication.^{16,17} Nevertheless, the production costs are low, including polymeric resin, metal powder and software related – fees.

Conclusion

The presented approach is a safe, effective and cost-efficient method to allow fully-guided OMS placement and is independent of screw material or dimensions. However, further clinical data may need to be collected to promote use of this approach.

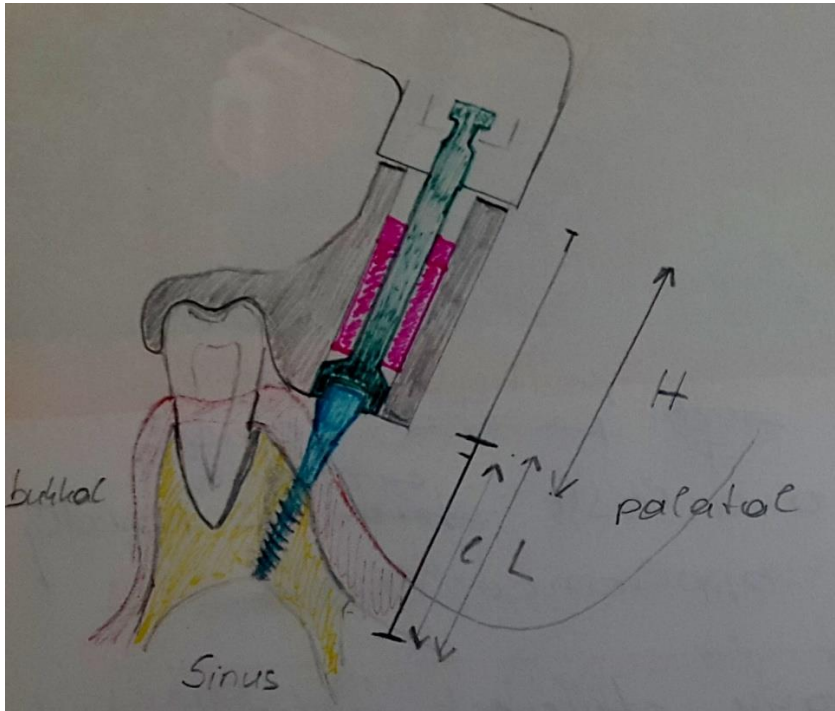


Figure 1: The image depicts the surgical procedure with the designed guide to determine the depth and angulation.



Figure 2: Application instrument with metallic shaft sleeve

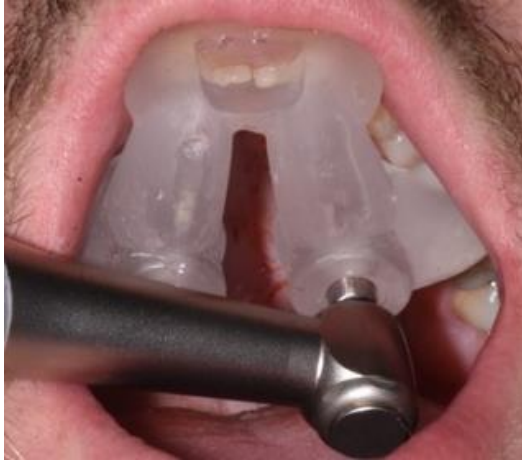

Figure 3: Guided insertion using a pre-fabricated splint

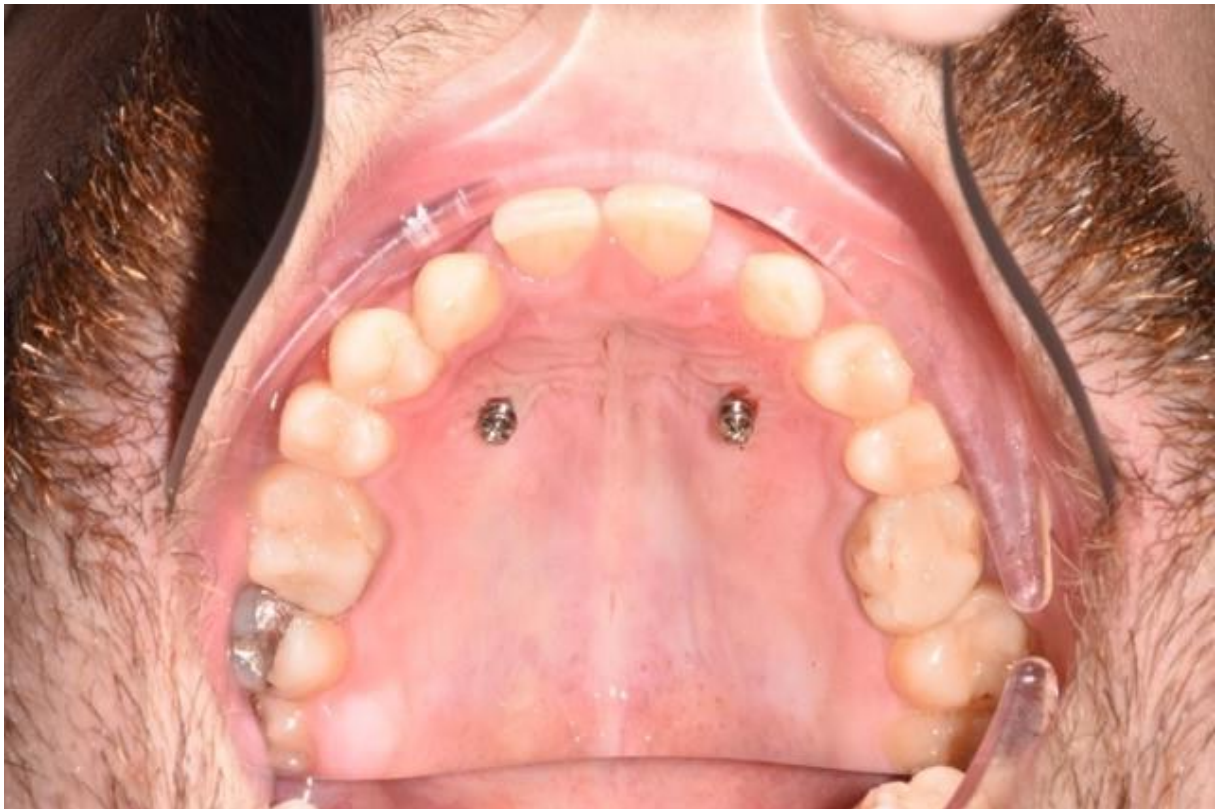

Figure 4: Postoperative view after guided insertion of OMS

References:

- (1) Winsauer H, Vlachojannis C, Bumann A, Vlachojannis J, Chrubasik S. Paramedian vertical palatal bone height for mini-implant insertion: a systematic review. *Eur J Orthod* 2014 Oct;36(5):541-549.
- (2) Schaetzle M, Maennchen R, Zwahlen M, Lang NP. Survival and failure rates of orthodontic temporary anchorage devices: a systematic review. *Clin Oral Implants Res* 2009 Dec;20(12):1351-1359.
- (3) Baumgaertel S. Quantitative investigation of palatal bone depth and cortical bone thickness for mini-implant placement in adults. *Am J Orthod Dentofacial Orthop* 2009 Jul;136(1):104-108.
- (4) Chang HP, Tseng YC. Miniscrew implant applications in contemporary orthodontics. *Kaohsiung J Med Sci* 2014 Mar;30(3):111-115.
- (5) Kuroda S, Tanaka E. Risks and complications of miniscrew anchorage in clinical orthodontics. *Japanese Dental Science Review* 2014;50:79-85.
- (6) Ludwig B. The Possibility of Skeletal Anchorage. *J Clin Orthod* 2017 Sep;51(9):513-515.
- (7) Kravitz ND, Kusnoto B. Risks and complications of orthodontic miniscrews. *Am J Orthod Dentofacial Orthop* 2007 Apr;131(4 Suppl):S43-51.
- (8) Kravitz ND, Kusnoto B. Placement of mini-implants with topical anesthetic. *J Clin Orthod* 2006 Oct;40(10):602-4; quiz 599.
- (9) Papageorgiou SN, Zogakis IP, Papadopoulos MA. Failure rates and associated risk factors of orthodontic miniscrew implants: a meta-analysis. *Am J Orthod Dentofacial Orthop* 2012 Nov;142(5):577-595.e7.
- (10) Ahmed VKS, Rooban T, Krishnaswamy NR, Mani K, Kalladka G. Root damage and repair in patients with temporary skeletal anchorage devices. *Am J Orthod Dentofacial Orthop* 2012 May;141(5):547-555.
- (11) Moghadam HG, Caminiti MF. Life-threatening hemorrhage after extraction of third molars: case report and management protocol. *J Can Dent Assoc* 2002 Dec;68(11):670-674.
- (12) Jung YR, Kim SC, Kang KH, Cho JH, Lee EH, Chang NY, et al. Placement angle effects on the success rate of orthodontic microimplants and other factors with cone-beam computed tomography. *Am J Orthod Dentofacial Orthop* 2013 Feb;143(2):173-181.

(13) Cassetta M, Altieri F, Di Giorgio R, Barbato E. Palatal orthodontic miniscrew insertion using a CAD-CAM surgical guide: description of a technique. *Int J Oral Maxillofac Surg* 2018 Apr 10.

(14) Winsauer H, Muchitsch AP, Winsauer C, Milnes R, Vlachojannis J, Walter A. The TopJet for routine bodily molar distalization. *J Clin Orthod* 2013 Feb;47(2):96-107; quiz 139-40.

(15) Koop R, Vercruyssen M, Vermeulen K, Quirynen M. Tolerance within the sleeve inserts of different surgical guides for guided implant surgery. *Clin Oral Implants Res* 2013 Jun;24(6):630-634.

(16) Kuehl S, Payer M, Zitzmann NU, Lambrecht JT, Filippi A. Technical accuracy of printed surgical templates for guided implant surgery with the coDiagnostiX software. *Clin Implant Dent Relat Res* 2015 Jan;17 Suppl 1:e177-82.

(17) Laederach V, Mukaddam K, Payer M, Filippi A, Kuehl S. Deviations of different systems for guided implant surgery. *Clin Oral Implants Res* 2017 Sep;28(9):1147-1151.